



Surgery in Motion

The Use of Polymer (Hem-o-lok) Clips for Management of the Renal Hilum During Laparoscopic Nephrectomy

Hervé Baumert^{a,b,*}, Andrew Ballaro^b, Carlos Arroyo^a, Amir V. Kaisary^b,
 Peter F.A. Mulders^c, Ben C. Knipscheer^c

^a Department of Urology, Fondation Hôpital Saint Joseph, Paris, France

^b Department of Urology, Royal Free Hospital, London, United Kingdom

^c Department of Urology, UMC St Radboud, Nijmegen, The Netherlands

Article info

Article history:

Accepted December 23, 2005

Published online ahead of
 print on February 24, 2006

Keywords:

Laparoscopy
 Nephrectomy
 Renal vein
 Ligation

Abstract

Objective: Control of the renal pedicle is the most challenging step during laparoscopic nephrectomy. The standard method is to clip the artery and control the vein with an endovascular gastrointestinal anastomosis stapler. However, this device is expensive and has been reported to malfunction, leading to major complications even death. We describe an easy, quick, and cost-effective alternative technique.

Methods: From June 2002 to July 2005, two surgeons used this simplified technique to control the renal vein during laparoscopic nephrectomy. After pedicle dissection and control of the artery with a clip, the vein was grasped and gently pulled with a laparoscopic Babcock to reduce its diameter. Two Hem-o-lok clips (Weck Closure Systems, Research Triangle Park, NC) were easily placed on the renal vein, which was then transacted safely.

Results: We used this technique successfully for 130 consecutive laparoscopic nephrectomies (10 simple, 47 radical, 7 nephroureterectomies, and 66 live donor nephrectomies). No perioperative complications occurred with this technique in this series. There was no increase in the warm ischemia time when used during laparoscopic live donor nephrectomy.

Conclusions: The Hem-o-lok technique is easy, safe, and rapid and offers cost savings when compared to the endovascular gastrointestinal anastomosis stapler. We recommend its use during laparoscopic nephrectomy and live donor nephrectomy.

© 2006 Elsevier B.V. All rights reserved.

* Corresponding author. Department of Urology, Hôpital Saint Joseph, 185 Rue Losserand, 75014 Paris, France. Tel. +33 144 127 669.
 E-mail address: baumertherve@yahoo.fr (H. Baumert).

1. Introduction

Since the first laparoscopic simple nephrectomy was reported by Clayman et al. [1], the laparoscopic approach has been developed for all indications of kidney removal. Laparoscopic nephrectomy is now the recommended procedure for stage T1–T2 renal cell carcinomas [2,3], and the development of laparoscopic live donor nephrectomy has increased the popularity of kidney donation [4] with equivalent results to the open technique [5]. Nephroureterectomy may also be performed laparoscopically with equivalent oncologic results but with reduced pain and recovery time compared with the open procedure [6].

Laparoscopic nephrectomy is considered technically difficult because of the surgical risk during the pedicle management [7]. Most laparoscopists use titanium or polymer clips to control the artery, and the endovascular gastrointestinal anastomosis stapler (endo-GIA) to control the vein [8]. However, this stapling device can malfunction and lead to severe morbidity; it is also expensive [9–12]. Here we describe a series of laparoscopic nephrectomies performed by ligating both the renal vein and artery using polymer clips.

2. Materials and methods

Between June 2002 and July 2005, two surgeons performed laparoscopic nephrectomies using Hem-o-lok clips (Weck Closure Systems, Research Triangle Park, NC) to control both the artery and the vein. The Hem-o-lok clip includes one “tooth” at its extremity, which allow secure closure (Fig. 1). Both the renal artery and vein were dissected separately; the




Fig. 1 – Photograph shows the Hem-o-lok clip.

extent of the dissection of the vein was similar to that prior to endo-GIA ligation. One 10-mm Hem-o-lok clip was applied to the renal artery. The renal vein was then lightly grasped by closing the jaws of a 5-mm laparoscopic Babcock behind it and gently pulled so that the diameter of the vein was reduced sufficiently to allow two 10-mm Hem-o-lok clips to be applied with the free hand (Fig. 2). A third, lateral clip (not used during live donor nephrectomy) was placed in the same way on the renal vein distally to avoid back bleeding after vein transection. Once the vein had been divided it was easier to further dissect the renal artery and place one or two additional Hem-o-lok clips.

3. Results

A total of 130 laparoscopic nephrectomies were performed using this technique (Table 1). Control

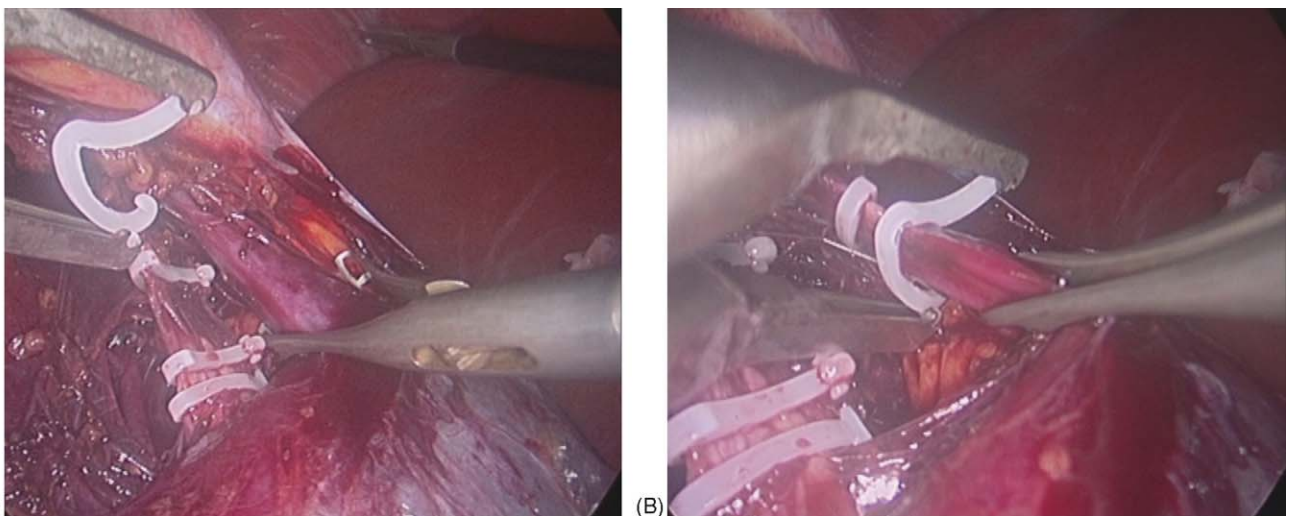


Fig. 2 – (A and B) Photographs show control of the renal vein with a laparoscopic Babcock to reduce the venous diameter and facilitate the positioning of the Hem-o-lok clip.

Table 1 – Classification of the type of laparoscopic nephrectomy using the Hem-o-lok clip

Procedure	Right side	Left side	Total
Simple nephrectomy	2	8	10
Radical nephrectomy	23	24	47
Nephroureterectomy	3	4	7
Live donor nephrectomy	11	55	66
Total procedures	39	91	130

and ligation of the renal vein was achieved with the Babcock and Hem-o-lok in all cases, and we found the clips easy to apply. Grasping the vein with the Babcock and applying two or three clips took, most of the times, less than 1 min. There were no perioperative complications or significant bleeding from the pedicle in this large series. The operative time appeared shorter than when using the endo-GIA. The median warm ischemia time during live donor nephrectomies was 4 min. All transplant kidneys recovered normal renal function quickly, and no renal vein thrombosis occurred.

4. Discussion

The complication rate associated with using the endo-GIA to ligate the renal vein has been reported to be between 1% and 1.7% and leads to morbidity in 45% of cases, a 20–27% conversion rate, and need for transfusion in 15% [10,12]. The majority of endo-GIA complications are likely to be contributed to by poor instrument handling or by choosing an incorrect staple width. To reduce the risk of complications, at least 3 cm of the vein must be dissected to enable correct positioning of the stapler prior to vein ligation. This can be difficult on the right side because of the short venous length. On the left side, care must be taken to avoid clips previously used for gonadal, adrenal, or lumbar veins, as a previously placed endo-clip trapped between the jaws of the stapler may cause the endo-GIA to malfunction and cut the renal vein without applying the clips. The primary malfunction rate of the stapler has been estimated at between 0.3% and 0.5% [9,10].

Several alternatives to the endo-GIA stapler when ligating the renal vein have been described during the development of laparoscopic nephrectomy. Kadirkamanathan reported knotting the renal pedicle intracorporeally [13], and both the Harmonic scalpel and bipolar diathermy have been tested on a pig model [14]. All techniques were found unreliable. Janetschek et al. described extracorporeally knotting the renal vein to reduce its diameter before applying Hem-o-lok clips and successfully used the techni-

que during 20 nephrectomies [15]. The knot was pushed down around the renal vein with a knot pusher, and this had to be performed with care to avoid damage to the vein. In this study knotting the vein took on average 2 min, precluding its use during live donor nephrectomy to minimize the warm ischemia time. Recently, others have adapted the Janetschek technique by manually compressing the renal vein prior to Hem-o-lok clip placement during hand-assisted laparoscopic nephrectomy [16,17].

Controlling the renal vein with the laparoscopic Babcock prior to clip placement in the present series allowed its diameter, which is generally greater than 10 mm to be reduced sufficiently for the clips to be applied safely. Gentle traction with the Babcock created a space behind the vein that improved visualization of the end of the clip during closure, reducing the risk of damaging the vein with the distal closure mechanism of the clip. Larger Hem-o-lok clips exist and could be used, negating the need for the Babcock to constrict the vein prior to clip placement. However the larger clips also require a larger applicator and because 10-mm clips are usually the ideal size for the renal artery, their use would result in increased costs. It is possible to remove a badly positioned clip with a specially designed grasper; however, in our experience this was not required. The only precaution that should be considered with this technique is to avoid damaging aberrant lumbar or adrenal vessels with the jaws of the Babcock.

Using only Hem-o-lok clips to ligate the renal hilum has significant cost advantages compared with using the endo-GIA stapler. The cost of the clip applicator, which is reusable, is 1160 Euros, and it is advisable to also purchase the clip remover at 985 Euros, although this instrument was not required in our series. One Hem-o-lok clip cartridge containing six clips costs 20 Euros, and up to two cartridges are required per nephrectomy. The extra costs of sterilizing the clip applicator are nil because it can be incorporated into any instrument tray, and the cost of its prior decontamination can be estimated at 20 Euros for the manpower involved and cleaning agent. The cost of the endo-GIA stapler, which is disposable, together with two clip cartridges sufficient for both the artery and vein (using clips for the artery and the endo-GIA for the vein would be more expensive) is 245 Euros. Therefore, cost savings of using clips instead of the stapler accumulate after 12 nephrectomies if the clip remover is purchased and 7 nephrectomies if it is not.

We found the Hem-o-lok technique faster than applying the endo-GIA and the pedicle could

generally be dissected, ligated, and divided in about 10 min. It was also technically easier than using the endo-GIA, particularly in the confined space of the retroperitoneal approach to the kidney. In our hands, using Hem-o-lok clips allowed a significant longer length of renal vein to be removed with the kidney during live donor nephrectomy because the applicator was less bulky and less difficult to position on the vein than the endo-GIA as reported by Chueh et al. [18]. In our series there was no renal vein thrombosis and the warm ischemia time was similar when the same surgeon used the endo-GIA stapler instead of the Hem-o-lok clips. An additional benefit of the Hem-o-lok clip is that it fits into a 10-mm port, compared to a 12-mm port required for an endo-GIA stapler, and its use was found to be associated with less tremor than when using the endo-GIA, which has a 5-mm stem through the larger port.

5. Conclusion

Using the Hem-o-lok clip to ligate both the renal artery and vein with prior constriction of the vein using a Babcock is an easy and reliable technique that allows quicker, safer, and more cost-effective control of the renal vein during a laparoscopic nephrectomy, compared to the use of the endo GIA stapler or other published methods. We recommend its use during simple or radical nephrectomy and live donor nephrectomy.

Appendix A. Supplementary data

Supplementary data associated with this article can be found, in the online version, at [doi:10.1016/j.eururo.2005.12.073](https://doi.org/10.1016/j.eururo.2005.12.073) and via www.europanurology.com. Subscribers to the printed journal will find the supplementary data attached (DVD).

References

- [1] Clayman RV, Kavoussi LR, Soper NJ, et al. Laparoscopic nephrectomy: initial case report. *J Urol* 1991;146:278–82.
- [2] European Association of Urology guidelines. http://www.uroweb.nl/files/uploaded_files/guidelines/laparoscopy.pdf.
- [3] Wille AH, Roigas J, Deger S, Tullman M, Turk I, Loening SA. Laparoscopic radical nephrectomy: techniques, results and oncological outcome in 125 consecutive cases. *Eur Urol* 2004;45:483–8.
- [4] Schweitzer EJ, Wilson J, Jacobs S, et al. Increased rates of donation with laparoscopic donor nephrectomy. *Ann Surg* 2000;3:392–400.
- [5] Wolf Jr JS, Merion RM, Leichtman AB, et al. Randomized controlled trial of hand-assisted laparoscopic versus open surgical live donor nephrectomy. *Transplantation* 2001;72:284–90.
- [6] Rassweiler JJ, Schulze M, Marrero R, Frede T, Palou Redorta J, Bassi P. Laparoscopic nephroureterectomy for upper urinary tract transitional cell carcinoma: is it better than open surgery? *Eur Urol* 2004;46:690–7.
- [7] Guillonnet B, Abbou CC, Doublet JD, et al. Proposal for a European Scoring System for Laparoscopic Operations in Urology. *Eur Urol* 2001;40:2–6, discussion p. 7.
- [8] Chan DY, Su LM, Kavoussi LR. Rapid ligation of renal hilum during transperitoneal laparoscopic nephrectomy. *Urology* 2001;57:360–2.
- [9] United States Federal Drug Administration Manufacturer and User Facility Device Experience Database (MAUDE); Available at <http://www.fda.gov/cdrh/maude.html>.
- [10] Chan D, Bishoff JT, Ratner L, Kavoussi LR, Jarrett TW. Endovascular gastrointestinal stapler device malfunction during laparoscopic nephrectomy: early recognition and management. *J Urol* 2000;164:319–21.
- [11] Soulie M, Salomon L, Seguin P, et al. Multi-institutional study of complications in 1085 laparoscopic urologic procedures. *Urology* 2001;58:899–903.
- [12] Deng DY, Meng MV, Nguyen HT, Bellman GC, Stoller ML. Laparoscopic linear cutting stapler failure. *Urology* 2002;60:415–20.
- [13] Kadirkamanathan SS, Shelton JC, Hepworth CC, Laufer JG, Swain CP. A comparison of the strength of knots tied by hand and at laparoscopy. *J Am Coll Surg* 1996;182:46–54.
- [14] Landman J, Kerbl K, Rehman J, et al. Evaluation of a vessel sealing system, bipolar electrosurgery, harmonic scalpel, titanium clips, endoscopic gastrointestinal anastomosis vascular staples and sutures for arterial and venous ligation in a porcine model. *J Urol* 2003;169:697–700.
- [15] Janetschek G, Bagheri F, Abdelmaksoud A, Shekhar Biyani C, Leeb K, Jeschke S. Ligation of the renal vein during laparoscopic nephrectomy: an effective and reliable method to replace vascular staplers. *J Urol* 2003;170:1295–7.
- [16] Eswar C, Badillo FL. Vascular control of the renal pedicle using the Hem-o-lok polymer ligating clip in 50 consecutive hand-assisted laparoscopic nephrectomies. *J Endourol* 2004;18:459–61.
- [17] Meng MV, Freise CE, Kang SM, Duh QY, Stoller ML. Techniques to optimize vascular control during laparoscopic donor nephrectomy. *Urology* 2003;61:93–8.
- [18] Chueh SC, Wang SM, Lai MK. Use of Hem-o-lok clips effectively lengthens renal vein during laparoscopic live donor nephrectomy. *Transplant Proc* 2004;36:2623–4.